

## Adipofascial Flap Based on Reversed Sural Flow for Reconstruction of Soft Tissue Defects of the Foot and Leg

MOHAMMAD REDA AHMAD, M.D. and ALAA N. EL-SADEK, M.D.

The Department of General Surgery, Plastic and Reconstructive Surgery Unit, Faculty of Medicine, Zagazig University.

### ABSTRACT

**Background:** Nowadays, the usage of adipofascial and adipofasciocutaneous flaps based on reversed sural flow, for reconstruction of soft tissue defects becomes a rich material for discussion.

**Objective:** To compare between the two types of flaps as regard success, cosmesis, complications, in relation to sex, age, and size of defect.

**Patients and Methods:** A total number of 13 cases of soft tissue defects of foot and leg divided into two groups: Group A, operated by adipofascial reversed sural flap (4 males & 3 females). Group B, operated by adipofasciocutaneous reversed sural flap (4 males & 2 females).

**Results:** No significant difference between 2 groups of patient as regard age ( $p>0.05$ ). No significant relation between sex and incidence of complication ( $p>0.05$ ). No significant difference between the 2 groups as regard complication ( $p>0.05$ ).

**Conclusion:** There were no significant difference in versatility of both adipofascial and adipofasciocutaneous flaps as regard success and complications. The merit of only adipofascial flap is a less scarring and good cosmesis in the donor areas, so it is more accepted by ladies as a tool of reconstruction. Moreover, instructing the patients to avoid smoking during the postoperative period and insisting on supporting the limb in cast is very important for flap survival.

### INTRODUCTION

One of the major challenging problems, faced by the reconstructive surgeon is how to cover soft tissue defects having exposed bones and tendons in the lower third of the leg, ankle, heel, and foot [1].

*Numerous solutions have been proposed in last few years:* Local, distant, and free flaps, each one having its advantages and disadvantages. In 1992 Masquelet and colleagues [2] proposed the distally based sural island flap. Depending on anatomical

studies carried by Quenu and Lejars in 1892 on the relationship between the vascularization of cutaneous nerves and overlying skin, they described the use of skin island flaps supplied by the vascular axis of the sensory superficial nerves.

Bertelli and Khoury [3] later termed these “neurocutaneous flaps”. These flaps are raised in the lower extremity including the underlying deep fascia to ensure their viability. Consequently the most appropriate term for them is “neurofasciocutaneous flaps”. The distally based sural neurofasciocutaneous flap is based on the vascular contribution supplied by the arterial network that accompanies the sural nerve and on its neurocutaneous perforating branches [4].

The determining arteries of the vascular axis of this flap are the arteries accompanying the medial sural cutaneous nerve, the lateral sural nerve and the lesser saphenous vein which cross the posterior part of the leg [4].

Masquelet et al. [2] reported a distally based flap with reverse flow through the anastomosis between the median superficial sural artery and the lowermost perforator of the peroneal artery.

The superficial sural artery is accompanied by a pair of venae comitantes. About four to six perforators come from the peroneal artery and emerge to the surface, running in the crural septum, to supply the skin of the posterior leg. These perforators are located about 5cm proximal to the lateral malleolus. The medial sural nerve descends in close association with the lesser saphenous vein [5,6].

The nerve is supplied by the superficial sural artery in the upper one-third of the leg, and in the distal two-thirds, it is supplied by perforators of

the peroneal artery. This arterianervorum gives additional blood supply to the flap. The lesser saphenous vein drains from the dorsal venous arch of the foot and passes behind the lateral malleolus along with the sural nerve [7].

## PATIENTS AND METHODS

A total number of 13 patients were reconstructed with the distally based sural flap from October 2007 to February 2010. Our cases were divided into 2 groups:

*Group A:* Included 7 cases operated by adipofascial reversed sural flap.

*Group B:* Contained 6 patients for them adipofasciocutaneous reversed sural flaps were done.

In the rest of the cases, the flap was either tunneled or the intervening skin was opened and closed again over the pedicle. In one case of each group part of the pedicle of each flap was grafted to avoid undue tension. None of our flaps was reinnervated by means of neurotomy.

All cases received intravenous antibiotics, usually cephalosporine for 36 hours postoperatively. This was continued by oral antibiotics for 2 weeks [8].

### *Operative technique:*

All patients were marked after being placed in a prone position. A template from the defect was then transferred and marked on the flap's donor area. The course of the median sural nerve can be delineated by following the course of the lesser saphenous vein. A 3-5cm pedicle was drawn on both sides with the vein being the central axis. The pivot point was marked at about 5cm proximal to the lateral malleolus [9]. In the operating room a pneumatic tourniquet was used in all cases. Eight out of our all cases had spinal anesthesia and five cases, had general anesthesia. The incision started at the proximal edge of the skin paddle through the skin and fascia until the lesser saphenous vein is found and ligated. The vein and the sural nerve travel in different planes proximal to the midpoint of the leg with the vein being more superficial than the nerve [10]. The sural nerve and the accompanying artery are then found between the two gastrocnemius heads and elevated with the flap. At this point, methodology of flap raising was different; for adipofascial flaps elevation of the flap after dissection of overlying skin and a little portion of subcutaneous tissues was performed. But in adipo-

fasciocutaneous flaps, elevation of the skin paddle is completed and the pedicle is created. The remainder of the skin island is incised using a lazy S incision and bilateral flaps are elevated medially and laterally preserving enough adipose thickness on them.

The tourniquet is deflated and hemostasis using bipolar diathermy is achieved. Also at the end of these surgeries; it was different during closure of the wound. In first group, direct closure of the wound was performed. In the other group, a split thickness skin graft was applied at the site of flap elevation. Negative pressure drainage is used in the donor site and two Soft drains are inserted under the flap. Finally a splint is made and the patient is taken to the ward, where elevation of the limb under two pillows is strongly encouraged.

### *Statistical analysis:*

Statistical analysis was performed using the 15.0 version of SPSS statistical software for windows. Unpaired student t test used in the comparison between 2 groups in age. To assess the association between variables in incidence of complication, success, failure and sex, fisher exact test were used. *p*-values less than 0.05 were considered significant.

## RESULTS

No significant difference detected between 2 groups of patient as regard age ( $p>0.05$ ).

No significant difference between the 2 groups as regard complication ( $p>0.05$ ). No significant possible relation between sex and incidence of complication ( $p>0.05$ ).

For almost all cases the flap was successfully solved the problem in 12/13 of our cases. The only failed case, was smokers and difficult to control, moreover, he was the only patient who was not protected by usage of splint or cast. Distal delay of healing occurred in 3 cases, and the solution was repeated wound dressing, and healing achieved in a few weeks. Significant edema of foot happened in one case, which responded to conservative management.

As regard the second group, one case suffered from distal flap necrosis. For one case regrafting of the donor site was performed.

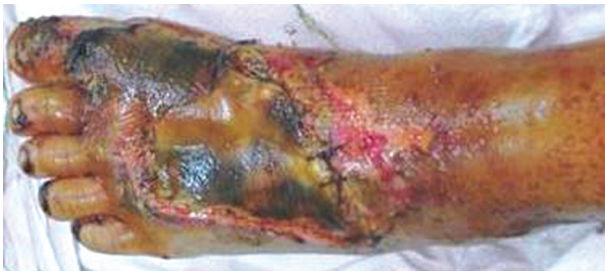

Fig. (1): Preoperative lesion.

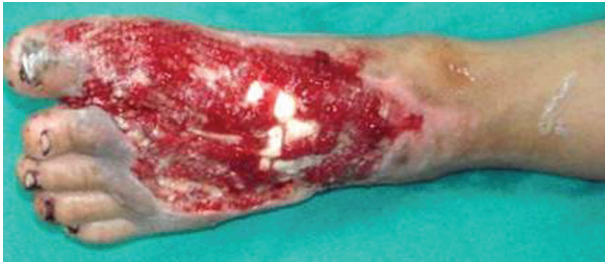

Fig. (2): After debridement.

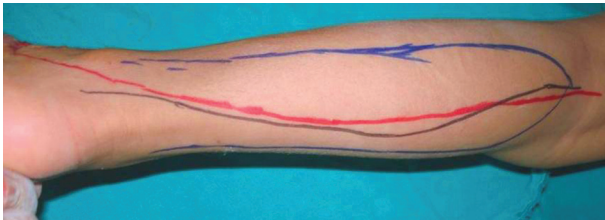


Fig. (3): Skin marking.

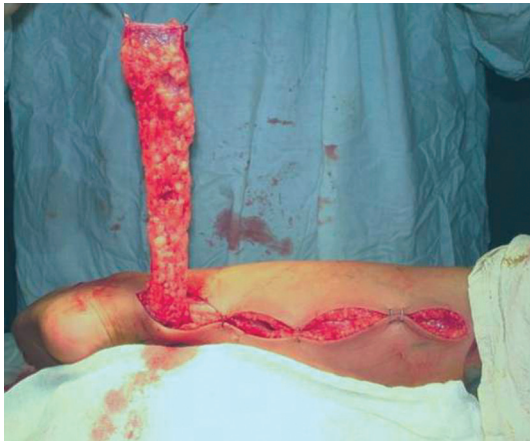

Fig. (4): Adipofascial flap raising.

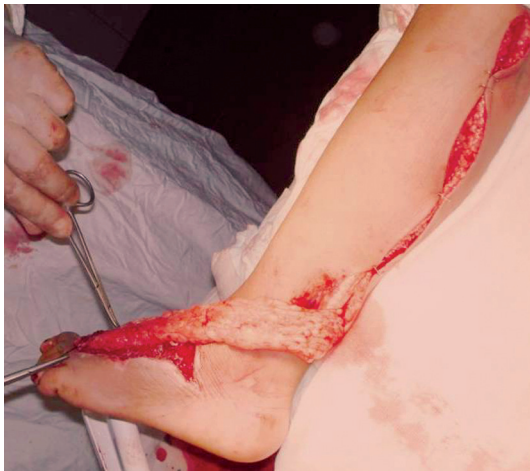

Fig. (5): Turning of the flap.

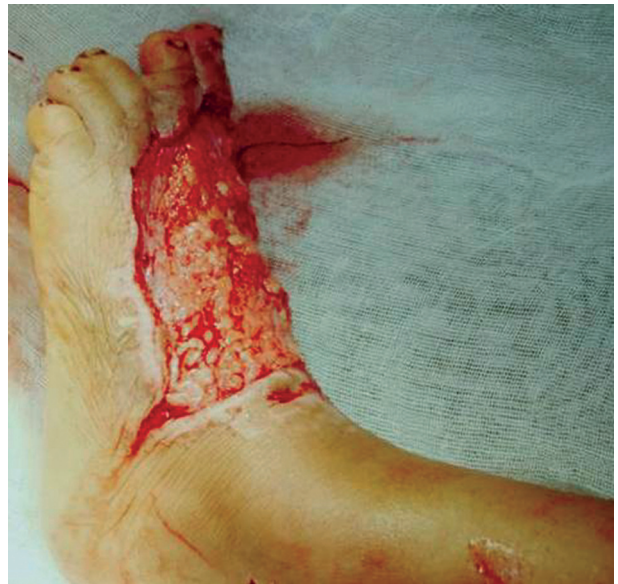

Fig. (6): Insitting of the flap.

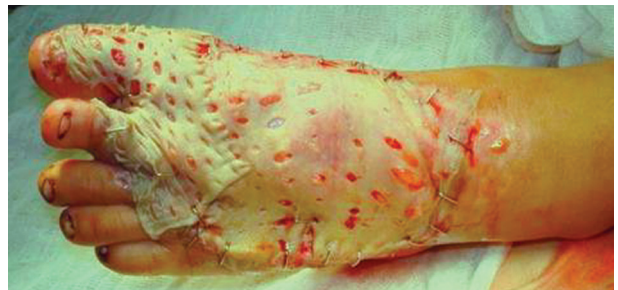

Fig. (7): Skin grafting.

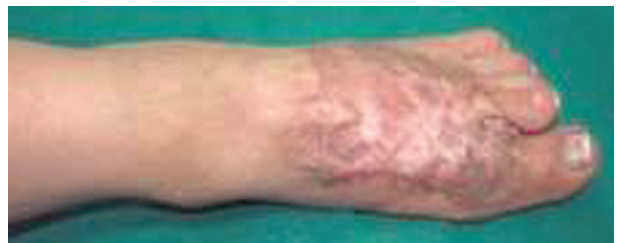

Fig. (8): 9 months postoperative results.

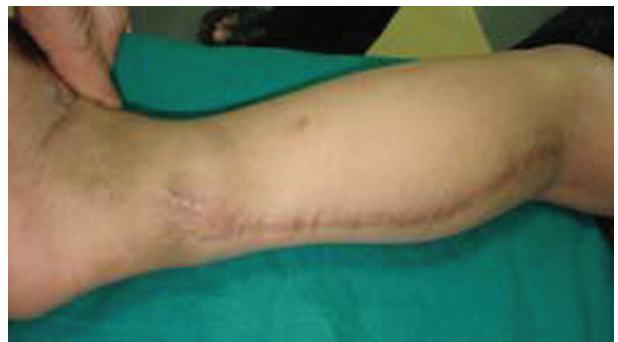

Fig. (9): Donor site 9 months postoperative.

Table (1): Patient details of the two groups.

Cases	Age/ sex	Defect's site	Nature of injury	Defect size (cm)	Flap dimensions (cm)	Results	Complications
1-A	6/m	Dorsum of the foot	Trauma	5X4.5	10X5	Success	Delayed healing at distal parts of flap, and little contracture
2-A	7/f	Medial side of foot	Trauma	3.5X4	8X4	Success	Non
3-A	5/m	Dorsum of foot	Trauma	5X6	10X6	Success	Limited distal flap necrosis, dressing only
4-A	17/m	Medial side of distal 1/3 of leg	Trauma	3X4	9X4 Part of the pedicle was grafted	Success	Non
5-A	34/m	Heal	Unstable scar	4X4.5	11X4 Flap's pedicle was exteriorized		Distal flap loss minor
6-A	42/f	Medial malleolus	Trauma	3X5	10X6	Success	Non
7-A	66/f	Heal	Neuropathic ulcer	4X5	19X6	Success	Oedema of foot for 3 months
8-B	7/m	Anterior surface of leg and ankle	Trauma	4X4	7X4 Part of the pedicle was grafted	Success	Non
9-B	8/f	Dorsum of foot	Trauma	3X4	8X4	Success	Non
10-B	40/m	Heal	Neuropathic ulcer	4X5	10X6 Flap's pedicle was exteriorized	Success	Regrafting of donor
11-B	52/m	Over tendoachilis	Trauma	6X5	11X6	Failed	Total necrosis of the flap in a patient did not adopt a good position
12-B	21/m	Heal	Unstable scar	6X5	14X6 Flap's pedicle was exteriorized	Success	Distal flap necrosis
13-B	37/f	Medial side of leg	Venous stasis	6X4	11X6	Success	Non

Table (2): Comparison between the results of two groups.

	Group A (n=7)		Group B (n=6)		p-value
	n	%	n	%	
♂	4	57.14	4	66.67	0.383 (NS)
♀	3	42.86	2	33.33	
Age (mean ± SE)	25.29±8.7		27.50±7.5		0.851 (NS)
Success	7	100%	5	83.33	0.462 (NS)
Failed	—	—	1	16.67	
Complication	4	57.14	3	50	0.617 (NS)

## DISCUSSION

Soft tissue defects with exposed bone or tendons involving the lower part of the leg, ankle, and foot remain a challenging problem for all surgical specialities (general, trauma, orthopedic, plastic). Trauma is the main cause of this problem [1].

In the reconstructive ladder there are many different options available such as skin graft, local flaps, regional flaps, and free flaps. Skin grafts can not be used if there is exposed bone and tendons. Local flaps can be used but they have a limited arc of rotation. Reverse pedicle flaps such as anterior tibial, posterior tibial, and peroneal artery flaps entail sacrificing the major arteries. Free flaps result in good coverage but may add unnecessary bulk resulting in poor contour and other mechanical problems, and they require expertise and longer operative time. On the other hand, the reversed sural artery flap is a thin fasciocutaneous flap that can be easily elevated and has a long arc of rotation [1].

Sural neuro-fasciocutaneous flaps represent a solution that can be used for different reconstructive needs in the distal third of the leg. As it offered many advantages:

First, it is a simple and rapid operation performed in a single stage without requiring microsurgical techniques.

Second, the vascularization of the sural region is constant and safe and there is no need to sacrifice major arteries.

Third, the flap has a long pedicle, facilitates the transfer of the skin island to a defect at a distance from the donor area.

Forth, the thickness and quality of the flap are ideal for covering defects in the distal parts of legs and feet.

Fifth, the morbidity of the donor area is minimal with no significant functional loss.

Last, the postoperative recovery time is short [11].

Graf and Biemer [12] stated that, movable flap plastics are suitable for local soft tissue covering. These are useful for covering very small defects; therefore the indication spectrum is only a very limited one. Compared to the neurocutaneous flaps, muscle flap plastics, for example, the soleus flap and the flexor digitorum longus flap, offer the advantage of better blood circulation and thus stronger resistance to infection.

However, due to the thickness of the shifted tissue they lead to both functional and cosmetic problems.

Free flap plastics require high-standard operative resources and equipment. Therefore, these surgeries are conditioned to prerequisites which are not available in all hospitals, and above all the trained personnel necessary for microsurgical operations. In every case, it must be ensured that any operational interventions or revisions can be carried out competently at any time.

Freely transferred, microvascular attached transplants affect the arterial blood circulation of the foot via the connection to one of main vessels of the lower legs [12]. Particularly in diabetics and atherosclerotic patients insertion of pedicled flap plastics must be avoided, for example, a dorsalis pedis artery flap and a medial plantar flap, to avoid impairment of the blood circulation of the foot. The long operation time may be a contraindication in elderly patients. Cross-leg flaps, require long-lasting immobilization and entail a real threat of thrombosis and the development of a decubital ulcer [12].

Nakajima et al. [10] proved that, the position of the perforators arising from the peroneal artery is constant and easily identifiable through topographical references. In their opinion, this makes the routine Doppler study unnecessary except in patients with fractures of the distal one third of the leg or when an operation has been previously performed on the Achilles tendon; these situations may result in damage to the distal perforators.

If the recipient area is easily reached by the flap, there is no need to isolate the distal perforator; this is done when cover of the more distal areas through a longer pedicle is required. In this case, in addition to isolating the most distal perforator, it is better to dissect the intermuscular septum to reduce the tension on the pedicle and to minimize venous stasis. To ameliorate problems, mainly those caused by venous stasis, it is important to ensure that the subcutaneous tunnel is of suitable size for the sural flap transfer. The tunnel should be wide enough to accommodate at least four fingers. The anatomical basis of this flap and its vascularization indicates how important it is to keep an adipofascial pedicle of suitable length around the sural axis. It is clear now that in 35% of the anatomical dissections instead of a dominant sural artery accompanying the nerve there is a vascular network enforced by the arterial net surrounding the lesser saphenous vein [11-16]. As for the venous network, the preservation of a suitable pedicle width is so necessary. The drainage of the flap is performed mainly by a venous net allowing bypass of the venous valves of the lesser saphenous vein by communicating and collateral branches. For these reasons Parodi et al. [4] stated that the pedicle should have a minimum width of 4cm, generally extending to 6cm, to maximize flap vascularization which, in their opinion, should be included in a new kind of flap that we have named "axial assisted flap".

Concerning the morbidity of the operation, it must be mentioned that a possible hyposthesia at the lateral edge of the foot can occur due to the disconnection of the sural nerve. The operation does not result in functional restrictions since the gastrocnemius muscle is not impaired by the elevation of the fasciocutaneous flap [17].

Al-Qattan [18] advised to avoid flap undermining too proximal in the leg to achieve a first-rate result and the minimization of complications. This is a region where the flap has a random vascularization, and it may therefore undergo vascular complications. The position recommended by Al Qattan [18] for the preparation of the flap lies between the

proximal one-third and the distal two thirds of the leg; the sural artery starts its suprafascial course at this level [19]. In most cases this comprises the need to use the most distal perforator as a pivot point. This, according to various anatomical studies, seems to be constant and of suitable caliber [18,20].

Another idea stated by Dolph [13] entails that, Avoidance of tunneling together with limited flap undermining proximally allows a reduction in marginal necrosis. Total necrosis of the flap is unusual; in his only case it probably occurred due to venous stasis in a flap which had prior cutaneous expansion in order to increase the size of the donor area. There are conditions in which the use of the flaps is not recommended, the main ones being extensive trauma, wounds from penetration by high speed bodies, major defects and cases in which the conditions of the peroneal or sural arteries have been impaired.

According to Arnez, [21] the distally based sural neuro-fasciocutaneous flap is a very useful flap for covering small to medium sized skin/soft tissue defects in the distal one-third of the lower leg, over malleoli, and the posterior calcaneal region. It is used principally for reconstruction after skin/soft tissue necrosis following trauma. Its use is limited by the size of the defect. The sural flap is rarely indicated in emergency trauma cases, in particular when the zone of injury to the lower leg is large or cannot be ascertained properly. On the weight-bearing surfaces of the foot, in his opinion, the sural flap should be used as a tertiary option, after the medial plantar flap and free muscle flaps. In women the use of the sural flap should be limited to the cases in which direct donor closure is possible, and in our study the usage of only adipofascial flap with direct closure of wound is well accepted by ladies.

The problems associated with using the usual adipofasciocutaneous flap are related to the donor site scar. This is not well accepted, particularly in women, particularly because of the loss of sensation that arises when the medial sural nerve is cut. Fortunately, in the experience of Huisinga and his colleagues [22] this problem has never been of great importance to their patients.

*In Conclusion:* In our results we found that, firstly, there were no significant difference in versatility of both adipofascial and adipofasciocutaneous flaps as regard success and complications. The merit of only adipofascial flap is a less scarring and good cosmeses in the donor areas. Secondly, instructing the patients to avoid smoking during

the whole postoperative period and insisting on supporting the limb in cast is very important for flap survival.

## REFERENCES

- 1- Riaz Khan M., Govila A. and El Faki H.: Reversed superficial sural artery adipofasciocutaneous flap: Is it a versatile flap? *Eur. J. Plast. Surg.*, 29: 187-193, 2006.
- 2- Masquelet A.C., Romana M.C. and Wolf G.: Skin island flaps by the vascular axis of the sensitive superficial nerves: Anatomic study and clinical experience in the leg. *Plast. Reconstr. Surg.*, 89: 1115-1121, 1992.
- 3- Bertelli J.A. and Khoury Z.: Neurocutaneous island flaps in the hand: Anatomical basis and preliminary results. *Br. J. Plast. Surg.*, 45: 586, 1992.
- 4- Parodi P.C., DeBiasio F., Vaienti L., DeLorenzi F. and Riberti C.: Distally based sural neuro-fasciocutaneous island flap to cover tissue loss in the distal third of the leg *Eur. J. Plast. Surg.*, 26: 175-178, 2003.
- 5- Seng-Feng Jeng F.C., Wei C.H., Hsieh Y.R. and Kuo T.S.: Lin Distally based sural island flap. *Plast. Reconstr. Surg.*, 111: 840-841, 2003.
- 6- Aoki S., Tanuma K. and Iwakiri I.: Clinical and vascular anatomical study of distally based sural flap. *Ann. Plast. Surg.*, 61: 73-78, 2008.
- 7- Petros K. and Spyriounis: The use of the reverse sural neurovenocutaneous flap in distal tibia, ankle and heel reconstruction *Eur. J. Plast. Surg.*, 28: 309-314, 2005.
- 8- Owens C.D. and Stoessel K.: Surgical site infections: Epidemiology, microbiology and prevention. *J. Hosp. Infect.*, 70 (2): 3-10, 2008.
- 9- Bisson M.A., Spyriounis P.K. and Miller J.G.: Perforator-based flaps in distal upper and lower extremity defects. *Eur. J. Plast. Surg.*, 25: 86-90, 2002.
- 10- Nakajima H., Imanishi N. and Fukuzumi S.: Accompanying arteries of the lesser saphenous vein and sural nerve. Anatomic study and its clinical applications. *Plast. Reconstr. Surg.*, 103: 104-120, 1999.
- 11- Jeng S.F. and Wei F.C.: Distally based sural island flap for foot and ankle reconstruction. *Plast. Reconstr. Surg.*, 99: 744-750, 1997.
- 12- Graf P. and Biemer E.: Defektdeckung an den Extremitäten mit distal gestielten Lappenplastiken. *Chirurg*, 63: 964-972, 1992.
- 13- Dolph J.L.: The superficial sural artery flap in distal lower third extremity reconstruction. *Ann. Plast. Surg.*, 40: 520-522, 1998.
- 14- Hasegawa M., Torii S., Katoh H. and Esaki S.: The distally based superficial artery flap. *Plast. Reconstr. Surg.*, 93: 1012-1020, 1994.
- 15- Hyakusoku H., Tonegawa H. and Fumiiri M.: Heel coverage with a T-shaped distally based sural island fasciocutaneous flap. *Plast. Reconstr. Surg.*, 93: 872-876, 1994.
- 16- Cao W.G., Li S.L., Cheng K.X., Wang S.L. and Li Q.F.: The distally based posterolateral supramalleolar neuro-fasciocutaneous island flap for coverage defects over the distal third of the leg and foot. *European Journal of Plastic Surgery*, 33: 13-22, 2010.

- 17- Cormarck G.C. and Lamberty B.G.H.: A classification of fasciocutaneous flaps according to their patterns of vascularisation. *Br. J. Plast. Surg.*, 37: 80, 1986.
- 18- Al Qattan M.M.: A modified technique for harvesting the reverse sural artery flap from the upper part of the leg: Inclusion of a gastrocnemius muscle "cuff" around the sural pedicle. *Ann. Plast. Surg.*, 47: 269-278, 2001.
- 19- Rajacic N., Darweesh M., Jayakrishnan K., Gang R.K. and Jojic S.: The distally based superficial sural flap for reconstruction of the lower leg and foot. *Br. J. Plast. Surg.*, 49: 383-389, 1996.
- 20- Yilmaz M., Karatas O. and Ali-Barutcu: The distally based superficial sural artery island flap: Clinical experiences and modifications. *Plast. Reconstr. Surg.*, 102: 2358-2367, 1998.
- 21- Arnez Z.: Commentary on "Distally based sural neuro-fasciocutaneous island flap to cover tissue loss in the distal third of the leg" by Parodi et al. *Eur. J. Plast. Surg.*, 26 (4): 179-180, 2003.
- 22- Huisinga R.L., Houpt P., Dijkstra R. and Van Leeuwen J.B.: The distally based sural artery flap. *Ann. Plast. Surg.*, 41: 58-65, 1998.